

# Preoperative planning of proximal tibial fractures

Matej Cimerman, Anze Kristan, Matevz Tomazevic

Department of Traumatology, University Medical Centre Ljubljana, Zaloska 7, 1000 Ljubljana, Slovenia

We used EBS program for planning of surgical management of high energy proximal tibia fractures. Standard DICOM images were used and 3D model was made. The fracture fragments were segmented and the impressions were exactly measured. 10 consecutive cases were operated using this method. Preoperative plan was exactly followed in 8 cases. We found EBS software extremely valuable for these types of fractures.

Historically open reduction and internal fixation of high energy proximal tibia fractures have been associated with high rates of infection (13–88%) and nowadays staged protocol for management was proposed (1). Also articular step offs and angular deformities after operative treatment are observed in 10–19% of cases (2). Taking all this into account the complex tibial plateau fractures management remains very challenging for any orthopaedic or trauma surgeon. Traditionally the understanding of these fractures was based on two-dimensional classification systems (3), but CT based three-dimensional consideration of the fracture pattern is very important in the decision making regarding treatment. Luo (3) made a three column fixation concept based on 3D imaging of the fracture. Also other authors described new approaches especially the need for posterior one (2,3). With analogy to acetabular fractures it is impossible to present the whole tibial plateau with one surgical approach. Because of injured soft tissue envelope the separate surgical approaches should be carefully planned. Surgical fixation should take into consideration the biomechanics of the fracture (buttressing on the right site for example). So we assumed that accurate preoperative planning is of utmost importance in these difficult injuries. Using the staged protocol, the surgeon has some extra time which can be used for preoperative planning. We used EBS software for preoperative planning of high energy tibial plateau fractures.

## Material and methods

We have used EBS software (Ekliptik Ltd.). The program consists of three closely integrated tools, the 3D viewing tools, the segmentation tools and the reduction and fixation simulating tools. Data from CT of a fracture in DICOM format are used (1.5mm or 2.0mm slices). First the 3D model is made (Figure 1), and then segmentation is carried out (Figure 2, 3), where each fracture segment is made as an individual object. In reduction each fracture segment can be moved in all three directions, can be rotated in all planes and its pivot point of rotation can be changed.

This enables more “real intraoperative” feeling of reduction. After reduction fixation can be undertaken, either with plates that can be automatically contoured or with pre curved plates that are already in program database (Figure 4, 5). The plan of automatically contoured plates can be drawn and printed out in 1:1 scale. Some specific “surgeons” needs functions were added: cut out function enables to cut out all the bone in any plane of the screw, so the exact position of the implant in the bone can be studied, virtual C arm enables to simulate intraoperative view (Figure 6, 7).

All the steps can be carried out on a regular personal computer by the surgeon who is doing the preoperative planning. This is the complete novelty since segmentation can be carried out by the surgeon. In that way all the fracture lines are studied in 3D dur-

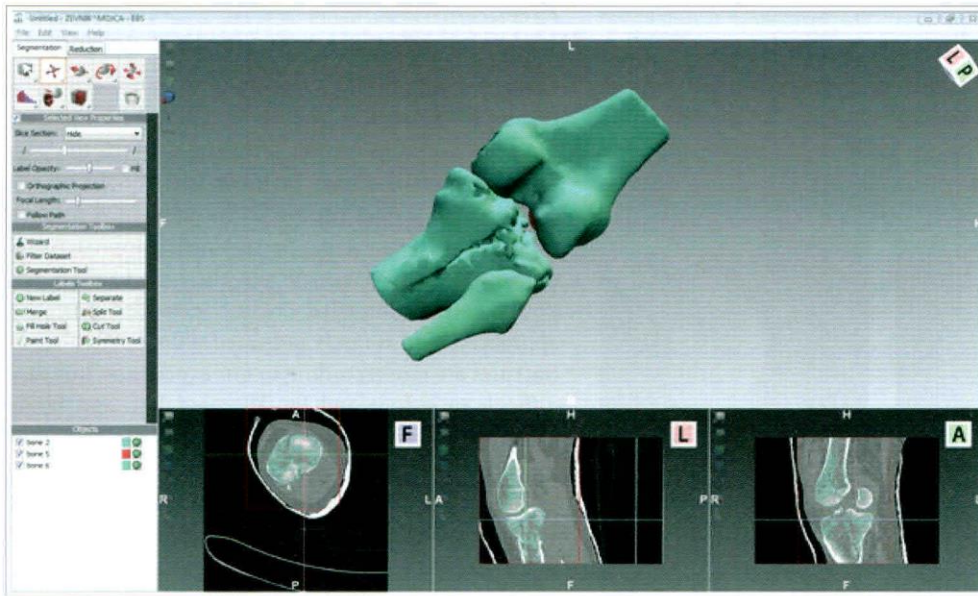


Figure 1: 3D model of proximal tibia fracture

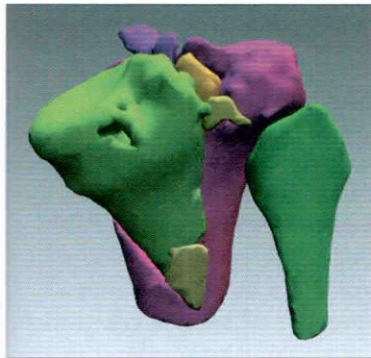


Figure 2: PA 3D view of segmented proximal tibia fracture

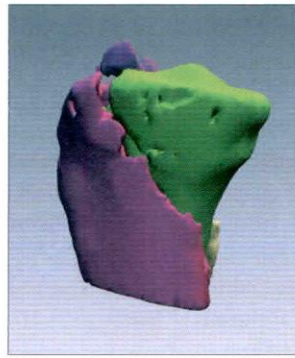


Figure 3: ML view of proximal tibia fracture

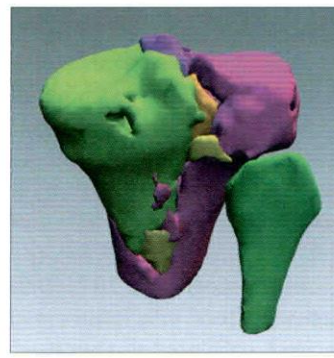


Figure 4: PA view of reduction.

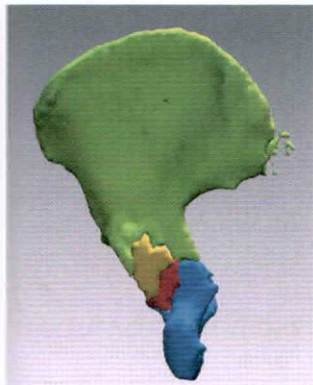


Figure 5: ML view of virtual reduction and fixation of proximal tibia fracture.

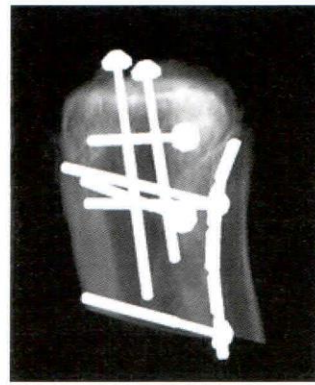


Figure 6: lateral view X-ray simulation of ORIF.

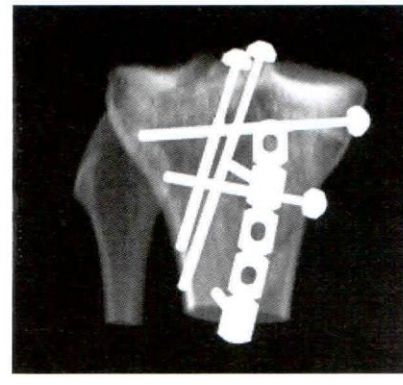


Figure 7: X-ray simulation of AP view of ORIF proximal tibia

ing segmentation process. The procedure is quick and easy.

We also educated five surgeons to use the program independently. The learning time for the education was one half day course composed of theoretical and practical exercises.

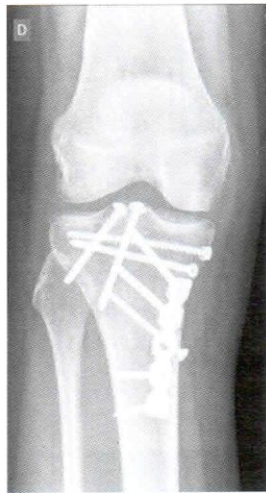

Figure 8: AP view after ORIF

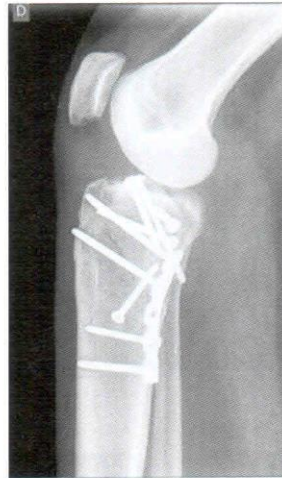

Figure 9: Lateral view after ORIF

## Results

We have used the program in 10 high energy proximal tibial fractures. Once only posteromedial approach was performed, once posterior approach according to Luo in combination with lateral approach was performed, once medial approach in combination with posterolateral approach with fibula osteotomy was performed, once posteromedial approach and arthroscopic fixation of intercondylar eminence was performed in other cases we combined posteromedial and lateral approach. We always performed the approach according to preoperative planning and we were able to reduce and fix all the fractures. We exactly followed the plan regarding the implants in 8 cases and made slight intraoperative changes in 2. (Figure 8, 9) We never made major changes regarding the planned reduction and implants. We were satisfied with the reduction in 9 out of 10 cases. All the surgeons found the program user friendly and described it as very advantageous in their practice.

## Discussion

Understanding of 3D anatomy of the proximal tibial fractures is extremely important. Using EBS software we realized that in complex fracture patterns the posterior column is always involved and should be addressed with proper approach. Posteromedial column can be fixed mostly using posteromedial approach and buttressing is biomechanically the best fixation option. For posteromedial column extended posterior approach (Luo) is rarely indicated. Pure posterolateral fractures are rare according to our experience, but very difficult to reduce and fix. We used Luo and fibula osteotomy approach, but we will consider Frosh approach in the future.

We found EBS planning tool extremely valuable for these types of fractures.

## References

1. Egol KA et al. Staged management of high-energy proximal tibia fractures (OTA types 41). *J Orthop Trauma*. 2005;19:448-455.
2. Frosch KH, Balcarek P, Walde T, Stuermer KM. A new posterolateral approach without fibula osteotomy for the treatment of tibial plateau fractures. *J Orthop Trauma*. 2010;24:515-520.
3. Luo CF, Sun H, Zhang B, Zeng BF. Three column fixation for complex tibial plateau fractures. *J Orthop Trauma*. 2010;24:683-692.